

Lung Cancer

Squamous Cell Carcinoma

Definition of Terms

Squamous cell lung carcinoma:

A type of cancerous, or malignant, tumor originating in the area of a lung airway.

Lobe: A spongy compartment of the lung. The right lung has three lobes, and the left has two.

Pathologist:

A physician who examines tissues and fluids to diagnose disease in order to assist in making treatment decisions.

Sputum: Mucus coughed up from the lungs.

What is Squamous Cell Lung Carcinoma?

Squamous Cell Lung Carcinoma is a type of non-small cell lung cancer formed from reserve cells – round cells that replaced injured or damaged cells in the lining of the bronchi, the lung’s major airways. Squamous cell tumors usually occur in the lung’s central portions or in one of the main airway branches. These tumors can form cavities in the lung if they grow to a large size.

Making up between 25 and 40 percent of all lung cancers, Squamous Cell Carcinoma can spread to bones, adrenal glands, the liver, small intestine or brain. The prognosis for an advanced stage of this type of lung cancer is not good. However, five-year survival rates can be as high as 35 to 40 percent for those who have localized lung cancer that is identified and removed in its early stages. These five-year survival rates approach 85 percent for patients under age 30.

Who is most likely to have Squamous Cell Lung Carcinoma?

This type of cancer is almost always caused by smoking. Secondary risk factors include age, family history, and exposure to secondhand smoke, mineral and metal dust, asbestos or radon. Both how much and how long a time you smoke increases the chances of lung cancer. If you quit smoking, your risk decreases over time.

What characterizes Squamous Cell Lung Carcinoma?

Slow growing, this type of cancer can take years to develop from a confined tumor to invasive cancer. Symptoms develop slowly as

well. They include coughing, shortness of breath, wheezing, chest pain and bloody sputum. Sometimes, this illness may appear at first to be pneumonia or a collapsed lung.

How does a pathologist diagnose Squamous Cell Lung Carcinoma?

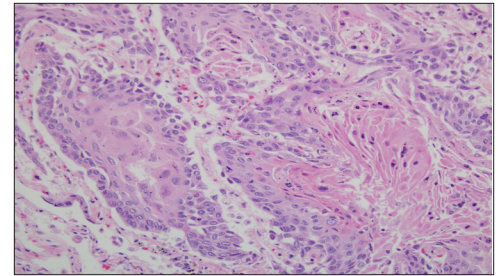
Your primary care physician will conduct a thorough physical examination and gather a sample of sputum for the pathologist to examine for traces of

blood, bacteria, infectious organisms and cancer cells. If the sputum test does not provide a definite diagnosis, your primary care physician may prescribe further tests, which may include a **chest x-ray** or

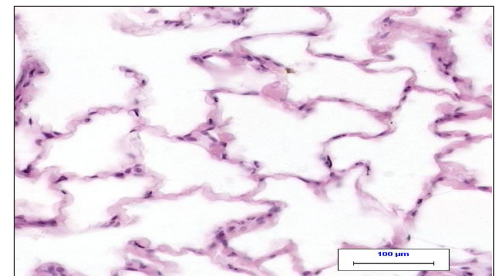
bronchoscopy. By viewing a chest x-ray, the radiologist can detect a mass in the lungs or enlarged lymph nodes in the chest.

Bronchoscopy is an examination of the windpipe and lung branches with a flexible scope.

If there appears there may be a mass in your lungs, your primary care physician or oncologist may order a **CT or MRI scan** or a **needle biopsy.** CT (computed tomography) or MRI (magnetic resonance imaging) scans produce chest images that assist
(continued on back)



Squamous Cell Lung Carcinoma (above) is a slow-growing cancer that can take years to develop into invasive cancer.



Normal lung cells (above).



Advancing Excellence

Copyright © 2006
College of American
Pathologists. For use and
reproduction by patients
and CAP members only.
First edition, Dec. 2006.

What kinds of questions should I ask my doctors?

Ask any question you want. There are no questions you should be reluctant to ask. Here are a few to consider:

- *Please describe the type of cancer I have and what treatment options are available.*
- *What is the stage of my cancer?*
- *What are the chances for full remission?*
- *What treatment options do you recommend? Why do you believe these are the best treatments?*
- *What are the pros and cons of these treatment options?*
- *What are the side effects?*
- *Should I receive a second opinion?*
- *Is your medical team experienced in treating the type of cancer I have?*
- *Can you provide me with information about the physicians and others on the medical team?*

pathologists to better determine the nature, position or extent of a mass. CT is also used to guide a needle biopsy, which gathers cell samples from a suspicious area for the pathologist to examine.

By reviewing these tests, your pathologist is able to rule out or confirm a diagnosis of cancer. If cancer exists, the pathologist can begin to determine whether or not it has spread.

What else does the pathologist look for?

Your pathologist may examine additional blood tests ordered by your primary care physician or specialist. These tests identify lung cancer “markers” – elements in the blood associated with lung cancer. Finding particular types of markers help the pathologist determine the exact type of cancer. Also, if fluid has accumulated in the chest, a pathologist may examine fluid sample obtained through a procedure.

How do doctors determine what surgery or treatment will be necessary?

If cancer is found by the pathologist, your primary physician or specialist may order a bone scan to see if the cancer has spread into your bones. If the cancer has not spread, a procedure called **mediastinoscopy** may be recommended. In this procedure, a physician examines tissues and organs in the middle of the chest with an endoscope, which is a small, flexible device with a camera. The endoscope is inserted into the chest through a small incision at the top of the breastbone. Lymph nodes from the middle chest area are usually removed during this procedure. If the pathologist does not find cancer cells in these nodes, your primary care physician or specialist may recommend surgery.

After reviewing the results of all your tests and procedures, your pathologist assigns a pathologic **stage** to your lung cancer. Stage 1 squamous cell carcinomas are small and confined to the lungs, and stage 4 tumors have spread beyond tissues and organs near the lungs. Stages between 2 and 3 describe conditions in between these two extremes.

Once the stage has been determined, your primary care physician or cancer specialist will discuss treatment options with you. If the cancer is located only in the lungs, surgery is generally recommended. Common lung cancer surgical procedures include **thoractomy** (opening the chest wall) or **median sternotomy** (cutting through the breastbone) during which lung tissue, one lobe, or an entire lung will be removed, depending on the size of the tumor. Recently, surgeons have developed less-invasive procedures to remove cancerous tissue. Most appropriate for stage 1 and 2 cancers localized in the chest area, **video-assisted thoracic surgery (VATS)** enables surgeons to remove tissue through smaller incisions.

For aggressive and widespread tumors, physicians usually recommend **chemotherapy** and **radiation therapy**. Chemotherapy delivers drugs throughout the body, slows the cancer’s progression and reduces pain. Chemotherapy can be used before and after surgery and can be combined with other treatments. Radiation therapy – pinpointed high-energy beams – can be used to shrink tumors or to destroy cancer cells that remain after surgery. This treatment is also used to relieve the symptoms of advanced lung cancer. In some cases, photodynamic therapy (the destroying of cancer cells with drugs activated by laser lights) or other therapies may be recommended.

It’s important to learn as much as you can about your treatment options and to make the decision that’s right for you.

Clinical trials of new treatments for Squamous Cell Lung Carcinoma may be found at www.cancer.gov/clinicaltrials. These treatments are highly experimental in nature but may be a potential option for advanced cancers.

For more information, go to: www.cancer.gov (National Cancer Institute), www.emedicine.com (from WebMD) or www.oncologychannel.com. Type the keywords **squamous cell lung carcinoma** or **lung cancer** into the search box.